

GENERAL DENTISTRY

May/June 2015



Exodontia

A retrospective study on the use of a dental dressing to reduce dry socket incidence in smokers

James T. Murph Jr., DMD ▪ Susan H. Jaques, DMD ▪ Alexander N. Knoell, DMD ▪ Geoffrey D. Archibald, DDS ▪ Stan Yang, PhD

This study assessed the effectiveness of using an oxidized cellulose dental dressing in order to reduce the rate of alveolar osteitis after posterior tooth extraction in smokers. Dry socket incidences of heavy smokers from 4 independent dental clinics, which routinely used oxidized cellulose dental dressings to mitigate dry socket formation between March 2011 and December 2012, were compiled and evaluated. All extraction sites healed uneventfully except for those cases that developed dry sockets. Overall, 1.7% of male patients and 2.2% of female patients developed dry sockets. No conclusive relationship was found between the number

of cigarettes smoked and dry socket formation among patients in this study. The results of this study were consistent with the view that gender, age, postextraction regimen, and multiple extractions affect dry socket formation. The results indicate that an oxidized cellulose dental dressing postextraction is a safe and effective method for mitigating dry socket formation among smokers.

Received: June 30, 2014

Revised: November 13, 2014

Accepted: February 16, 2015

A dry socket is characterized by the nonformation or early loss of a blood clot from a tooth extraction site before the wound has healed.¹ Clinically, dry socket formation is associated with intense pain, a foul smell, and the disappearance of blood clots from the socket after tooth extraction. Causative investigations of dry socket formation have often been complicated by the presence of multiple, interrelated risk factors, including patient age, gender, smoking status, practitioner's experience, effort of extraction, and postextraction treatment regimen (such as curetting). Generally, mandibular third molar extractions have exhibited the highest dry socket incidence due to the extensive effort required to extract the entrenched root structure.¹⁻³

Smoking is known to increase the risk of dry socket formation. In a study of mandibular third molar extractions, smokers were found to be 5 times as likely to develop dry sockets as nonsmokers.^{4,5} Studies have shown that the risk of dry socket formation increased with an increased daily consumption of cigarettes. Individuals who smoked on the day of

surgery or Postoperative Day 1 had the highest incidence of dry sockets.⁴ In a review of 1305 extractions among 805 patients performed in a dental training center, the incidence of dry sockets was significantly higher among smokers (12%) versus nonsmokers (4%).⁶ Tooth sectioning, smoking, and degree of smoking were found to be associated with the development of alveolar osteitis, with a significant odds ratio of 4.3, 4.5, and 12.3, respectively.⁷

Smoking affects blood coagulation, platelet aggregation, clotting dynamics, and fibrin structure.⁸⁻¹⁴ Smokers exhibit a decrease in oral leukocyte function, are less responsive to periodontal treatment, and exhibit reduced bleeding in the extraction socket.¹⁵⁻¹⁷ The suction action of smoking was hypothesized to affect the formation of dry sockets by disrupting or dislocating immature blood clots and by introducing foreign substances into the extraction site. However, suction using straws did not cause dry sockets when third molars were extracted, implying that the effect of smoking on dry socket formation was due to a biological cause rather than a mechanical one.¹⁸

Many preventive methods to reduce the prevalence of dry sockets have been reported with varying results. These methods include postextraction irrigation; the use of antibiotics, analgesics, antiseptic, and antifibrinolytic agents; as well as the placement of intra-alveolar dressings.¹⁹⁻³⁴ Drugs were either used alone or soaked into intra-alveolar dressings to facilitate the application and release of the agents.²⁶⁻³¹ Studies of Gelfoam (Pfizer, Inc.)—an intra-alveolar dressing—reported a reduction in dry socket formation in third molar extraction sites when impregnated with either tetracycline or lincomycin; however, no reduction was reported when Gelfoam was used alone or mixed with aminoacridine.^{31,32,35-38} Despite intensive research, the exact cause of dry socket formation, as well as an effective treatment to prevent its formation, remains uncertain.^{19-31,35-38}

Oxidized cellulose is a generic term referring to chemically oxidized cellulose material, whose properties depend upon the selection of the cellulosic material and the chemical oxidation methods employed. Several oxidized cellulose

Chart 1. Age distribution of male and female patients.

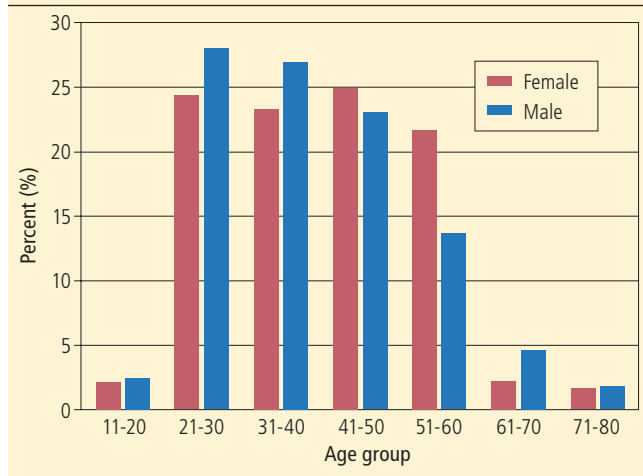
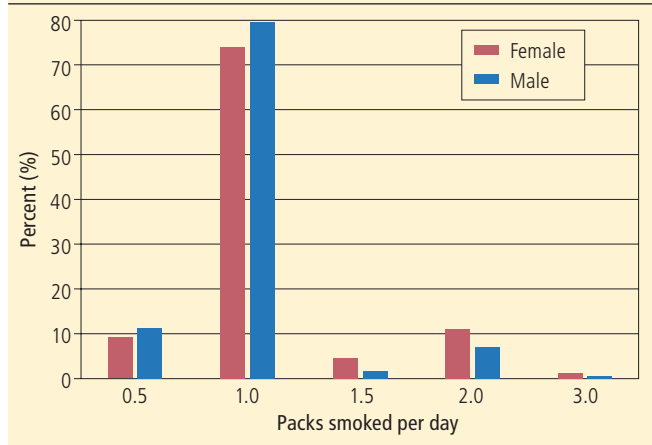


Chart 2. Percentage of patients based on the number of packs of cigarettes smoked per day.



products have been approved for clinical use as hemostatic wound dressings to control bleeding. However, not all oxidized cellulose products exhibit the same characteristics and performance. BenaCel oxidized cellulose dental dressing (Unicare Biomedical, Inc.) was cleared by the FDA for use as a wound dressing in extraction sites and for the management of dry sockets.³⁴ The present retrospective study was initiated after 1 of the original investigators identified a significant reduction in the dry socket rate among heavy smokers, who consumed 1 or more packs of cigarettes per day, after administering the oxidized cellulose dental dressing postextraction. The hypothesis was that an effective wound dressing material will aid in controlling bleeding by stabilizing blood clots, thus reducing the incidence of dry socket. The objective was to determine the safety and effectiveness of oxidized cellulose dental dressings in reducing dry socket incidence in a routine, noncontrolled, clinical setting. The dry socket incidence obtained from this study was then compared with values reported in the literature in order to evaluate the effectiveness of this method.

Materials and methods

This retrospective study compiled and analyzed the incidence of dry socket as recorded by 4 independent practitioners. These practitioners operated at their own clinics at separate locations in 3 different states (Minnesota, Tennessee, and South Carolina). Between March 2011 and December 2012, the practitioners routinely

used oxidized regenerated cellulose dental dressings to control bleeding and mitigate dry socket formation for high-risk patients, such as (but not exclusively) those taking blood thinners and smokers. One practitioner began the use of the dental dressing early and produced the bulk of the data during the full length of the study period. The remaining 3 practitioners did not use the dressing until the last 8 months of the study period and produced significantly less data. To focus on high-risk scenarios with subsequent higher dry socket incidences, the data of all smoking patients, whose extractions involved only posterior teeth (the first premolar to the third molar)—regardless of the systemic health of the patients and independent of whether they had diseases such as blood clotting disorders, hypertension, or diabetes—were included in the study. Each practitioner used his/her own preferred extraction and postextraction regimen. All extractions were traumatic, and no dental implants were performed immediately or planned following extraction. The common link was the use of oxidized regenerated cellulose dental dressings to alleviate dry socket formation for all patients.

Two forms of BenaCel (plugs, 5 mm x 7 mm; sheets, 15 mm x 15 mm) were used by the practitioners. Both forms are made of the same material and exhibit the same performance, differing only in their configurations.³⁴ Generally, sheets were used in third molar extractions and plugs were used in all other posterior sites, depending on the size of the extraction site and the doctor's preference.

According to the manufacturer's product information, the dental dressing material should dissolve, transforming into a gelatinous material after contact with blood, and then be absorbed within 5 days.³⁴ Depending upon the size of the extraction socket, 1-2 units of dental dressing were packed into the extraction site. The dental dressing was inserted into the apex of the extraction site without suture retention—unless the site was shallow or a surgical extraction was performed, in which case a crisscrossed suture was used to keep the dressing in the socket. A roll of wet sterile gauze was placed over the extraction site, and biting pressure was applied by the patient until the bleeding stopped.

In general, patients were instructed to refrain from smoking 1 day before extraction and for at least 1 day postextraction. Extractions were performed with patients under local anesthesia. Postextraction, 3 investigators curetted the sockets, while 1 investigator did not curette except when the site was infected. Patients were instructed to return for treatment if bleeding or excessive pain occurred. If a patient returned, a diagnosis of dry socket was made based on the following criteria: a constant, radiating pain 3-4 days postoperatively, partial or total absence of a blood clot, and/or tenderness upon palpation.

Dry socket incidences were analyzed for the following variables: patient age, gender, number of packs of cigarettes smoked per day, and curetting status.

Chart 3. Percentage of extractions based on extraction site.

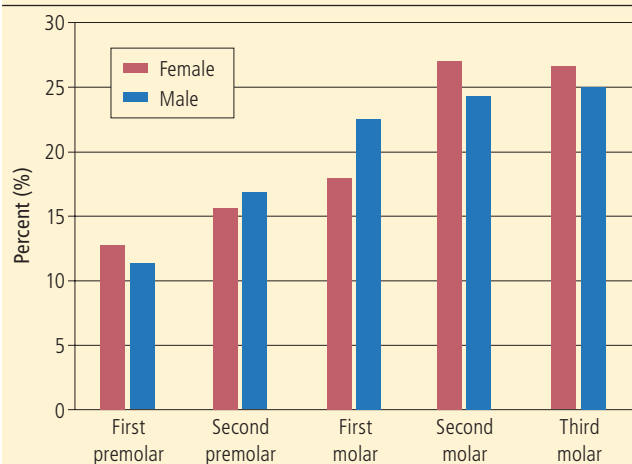


Chart 4. Dry socket incidence according to age bracket.

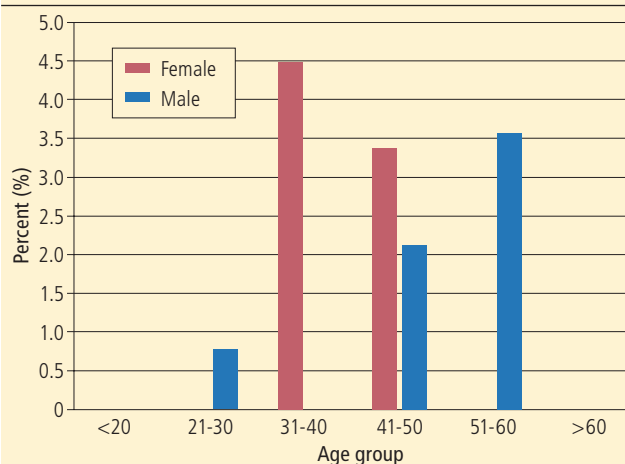
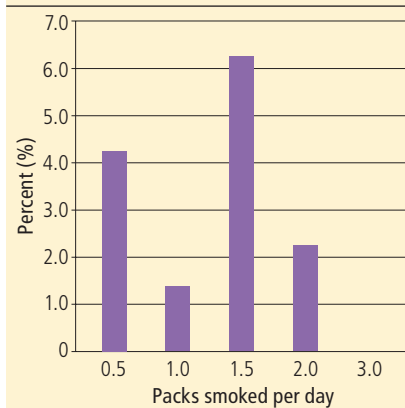


Table 1. Dry socket incidence according to gender.

Group	Number of patients	Number of dry sockets	Number of extractions	Percentage of patients with dry sockets
Male	287	5	440	1.7
Female	185	5 ^a	267	2.2
Total	472	10	707	1.9

^aOne patient developed 2 dry sockets from the same visit.

Chart 5. Dry socket incidence according to the number of packs of cigarettes smoked per day.



Results

The data of 472 patients (all smokers, with 707 posterior extractions performed) were used for this retrospective analysis. Of these procedures, 519 extractions (73%) were generated from 1 clinic, while 47 (7%), 64 (9%), and 77 (10%) extractions were collected from the remaining 3 clinics. The number of extractions reflects the experience and length of time the practitioners used the dressing during the study period and the demographic of the patient population for each clinic. Patients' ages ranged from 11 to 86. The average ages of male and female patients were 39 and 41 years of age, respectively, with men being a larger proportion of the sample (61%). More than 85% of patients were between 21 and 60 years of age (Chart 1). Each patient's smoking status was categorized by the number of packs smoked per day. On average, patients consumed 1.1 ± 0.4 packs of cigarettes each day, with a range of 0.5 to 3.0 packs per day. The majority

of patients smoked 1 pack of cigarettes per day (Chart 2). Second and third molar extractions constituted about 50% of all extractions (Chart 3). The remaining extractions included first molar, first premolar, and second premolar extraction sites. Overall, 71% of men and 68% of women received single extractions, and 22% of men and women received double extractions. The remaining patients had >2 extractions during the same visit.

Table 1 lists patient population, number of extractions, and the percentage of patients who developed dry sockets in accordance with the patients' genders. A total of 10 dry sockets developed in 9 of 472 patients with 707 extractions. Four female and five male patients experienced dry sockets postextraction. One 33-year-old woman who smoked 1 pack of cigarettes per day had 2 dry sockets after multiple extractions from the same visit. Overall, 1.7% of men (1.1% of extractions) and 2.2% of women (1.9% of extractions) developed dry sockets.

Chart 4 shows the percentage of patients in each age bracket that developed dry sockets. The 4 women, who developed a total of 5 dry sockets, were between 33 and 42 years of age; of these women, 2 each were between 33 and 40 (4.7%) and between 41 and 42 (4.4%) years of age. Five dry sockets occurred in 5 men who were between 27 and 54 years of age; of these men, 2 each were between the ages of 41 and 50 (3.0%) and between 51 and 60 (5.1%). One man between the ages of 21 and 30 (1.25%) also developed a dry socket.

Chart 5 depicts the prevalence of dry sockets versus the number of packs of cigarettes smoked by patients per day. The dry socket prevalence ranged from 1.4% for 1 pack per day smokers to 6.3% for 1.5

Table 2. Curetting, extraction, and dry sockets statistics per practitioner in study.

Practitioner ID	Curetting	Number of extractions	Number of dry sockets	Percentage of dry sockets
1	No	519	4	0.8
2	Yes	77	1	1.3
3	Yes	64	2	3.1
4	Yes	47	3	6.4
Total	-	707	10	1.4

packs per day smokers. The prevalences of dry sockets were 1.6% and 1.5%, respectively, for men and women who had single extractions, and 2.2% and 3.8%, respectively, for men and women who underwent 2 or more extractions during the same visit. The number of extractions performed by each practitioner and the practitioner’s postextraction regimen (curetting or noncuretting) along with the respective dry socket prevalences are listed in Table 2.

Discussion

This work is one of the earliest studies of the use of oxidized cellulose dental dressings to prevent dry socket formation in smokers. Although oxidized cellulose products such as Surgicel (Johnson & Johnson) have widely been used as hemostatic agents to control bleeding postextraction, there have been very few studies on the effectiveness of oxidized cellulose as a wound dressing to prevent or manage dry socket formation.³³ Suleiman reported that the use of an oxidized cellulose dressing increased dry socket incidence.³⁰ In contrast, the dressing used in the present study was found to be biocompatible and noninterfering with wound healing. The administration of the oxidized cellulose dental dressing was reported to be easy and noninvasive to the practitioner’s regular routine. All study sites achieved hemostasis before patients were discharged from the clinics. Other than the cases of patients who developed dry sockets, postoperative healing was uneventful. There were no reported instances of swelling, discomfort, infection, or prolonged bleeding caused by the use of the dental dressing. The wound healing characteristics of oxidized cellulose dressings observed in this study were similar to the results of a

preliminary retrospective study in which no postoperative bleeding, infections, or alveolitis were reported among 150 extractions from 118 patients, including both smokers and nonsmokers.³⁹

Dry socket incidence rates among smokers have been reported to range from 6.4% to 40.0% in mandibular third molar extractions and from 3.4% to 12.0% in general extractions, respectively.^{6,17,19,21,27,38,40} Dry socket incidence increases with increasing degrees of smoking, and patients who smoke immediately before or after tooth extraction have the highest incidence of dry socket formation.⁴ In the present study, approximately 90% of smokers smoked an average of 1 pack per day or more; these patients were considered “heavy” smokers. Despite emphatic instructions to refrain from smoking, the degree of patient compliance with these instructions could not be ascertained. It could be supposed that not all patients complied with the instructions, as some patients were observed smoking immediately after walking out of the clinics. Even so, the overall dry socket incidence rate for posterior extractions in smoking patients was 1.9%. Compared with the reported data in the literature, the relatively low incidence of dry sockets in this study support the hypothesis that oxidized cellulose dental dressings reduce dry socket incidence among smokers.

Female patients showed a slightly higher prevalence of dry sockets compared to male patients (2.2% versus 1.7%). The 4 women who developed dry sockets ranged in age between 33 and 42 years. Given the relatively low overall occurrence of dry sockets in the study, the concentration of dry socket patients in such a narrow age range was significant and suggested that adult, premenopausal female smokers are at an

increased risk of developing dry sockets. The 5 men who developed dry sockets ranged in age from 27 to 54. There appeared to be an upward trend in dry socket prevalence among male smokers as age increased, with the older (51 to 60) age group exhibiting a higher dry socket prevalence (5.1%) than other age groups (Chart 4).

There was no trending effect on dry socket incidence with regard to the number of packs of cigarettes consumed per day (Chart 5). However, as approximately 80% of patients smoked 1 pack of cigarettes per day, it cannot be concluded that there is any relationship between the number of packs of cigarettes smoked and dry socket prevalence.

The practitioner who produced the most data had the least amount of dry socket incidence. Thus, the experience of practitioners in extraction appears to affect the dry socket incidence. However, this factor is commingled with the postextraction curetting regimen, as the most experienced practitioner in this study did not curette the socket postextraction, while the remaining 3 practitioners did. Both male and female patients showed a higher prevalence of dry socket formation if the postextraction treatment regimen involved curetting. In addition, multiple extractions also resulted in higher percentages of dry socket formation among both genders.

Conclusion

The findings of this retrospective study are consistent with those reported in the literature, in that a patient’s gender, age, and postextraction regimen—along with practitioners’ experience—have been identified as factors affecting the prevalence of dry socket formation, even among smoking patients. While further studies are needed to substantiate the

results derived from this retrospective study, it can be concluded that the use of the oxidized cellulose dental dressing appears to be safe and effective in reducing dry socket formation among smokers. Adult, premenopausal female smokers and older male smokers emerged as groups who are at higher risk of developing dry sockets. Multiple extractions in 1 visit and postextraction curetting also resulted in higher dry socket incidences. The overall results appeared to indicate that the use of oxidized cellulose is effective in reducing dry socket incidence regardless of the patient's systemic health conditions and the practitioner's treatment modality.

Author information

Dr. Murph is in private practice in Conway, South Carolina, Dr. Jaques is in private practice in Holly Hill, South Carolina, Dr. Knoell is in private practice in Henderson, Tennessee, and Dr. Archibald is in private practice in North Branch, Minnesota. Dr. Yang works for Unicare Biomedical, Inc., Laguna Hills, California.

Disclosure

Unicare Biomedical, Inc. manufactures and sells BenaCel oxidized cellulose dental dressing, which is largely used in this study. For their efforts, Unicare Biomedical provided BenaCel at a discounted price to the doctors to carry out their procedures and to provide data for this study. In no other way did Unicare Biomedical, Inc. influence the results or behaviors of the doctors involved in this study.

References

1. Blum IR. Contemporary views on dry socket (alveolar osteitis): a clinical appraisal of standardization, aetiopathogenesis and management: a critical review. *Int J Oral Maxillofac Surg.* 2002;31(3):309-317.
2. Cardoso CL, Rodrigues MT, Ferreira Junior O, Garlet GP, de Carvalho PS. Clinical concepts of dry socket. *J Oral Maxillofac Surg.* 2010;68(8):1922-1932.
3. Kolokythas A, Olech E, Miloro M. Alveolar osteitis: a comprehensive review of concepts and controversies. *Int J Dent.* 2010;2010:249073.
4. Sweet JB, Butler DP. The relationship of smoking to localized osteitis. *J Oral Surg.* 1979;37(10):732-735.
5. Sweet JB, Butler DP. Predisposing and operative factors: effect on the incidence of localized osteitis in mandibular third-molar surgery. *Oral Surg Oral Med Oral Pathol.* 1978;46(2):206-215.

6. Abu Younis MH, Abu Hantash RO. Dry socket: frequency, clinical picture, and risk factors in a Palestinian dental teaching center. *Open Dent J.* 2011;5:7-12.
7. Bortoluzzi MC, Capella DL, Barbieri T, Marchetti S, Dresch CP, Tirello C. Does smoking increase the incidence of postoperative complications in simple exodontia? *Int Dent J.* 2012;62(2):106-108.
8. Ambrus JL, Mink IB. Effect of cigarette smoking on blood coagulation. *Clin Pharmacol Ther.* 1964;5:428-431.
9. Astrup P, Kjeldsen K. Carbon monoxide, smoking, and atherosclerosis. *Med Clin North Am.* 1974;58(2):323-350.
10. Billimoria JD, Pozner H, Metselaar B, Best FW, James DC. Effect of cigarette smoking on lipids, lipoproteins, blood coagulation, fibrinolysis and cellular components of human blood. *Atherosclerosis.* 1975;21(1): 61-76.
11. Allen RA, Kluff C, Brommer EJ. Effect of chronic smoking on fibrinolysis. *Arteriosclerosis.* 1985;5(5):443-450.
12. Hawkins RI. Smoking, platelets and thrombosis. *Nature.* 1972;236(5348):450-452.
13. Barua RS, Sy F, Srikanth S, et al. Effects of cigarette smoke exposure on clot dynamics and fibrin structure: an ex vivo investigation. *Arterioscler Thromb Vasc Biol.* 2010;30(1):75-79.
14. Moschos CB, Ahmed SS, Lahiri K, Regan TJ. Chronic smoking in an animal model. Effects on clotting and fibrinolysis. *Atherosclerosis.* 1976;23(3):437-442.
15. Eichel B, Shahrik HA. Tobacco smoke toxicity: loss of human oral leukocyte function and fluid-cell metabolism. *Science.* 1969;166(3911):1424-1428.
16. Jones JK, Triplett RG. The relationship of cigarette smoking to impaired intraoral wound healing: a review of evidence and implications for patient care. *J Oral Maxillofac Surg.* 1992;50(3):237-239; discussion 239-240.
17. Meechan JG, Macgregor ID, Rogers SN, Hobson RS, Bate JP, Dennison M. The effect of smoking on immediate post-extraction socket filling with blood and on the incidence of painful socket. *Br J Oral Maxillofac Surg.* 1988;26(5):402-409.
18. Bloomer CR. Straws do not cause dry sockets when third molars are extracted. *Tex Dent J.* 2012;129(1): 25-32.
19. Tolstunov L. Influence of immediate post-extraction socket irrigation on development of alveolar osteitis after mandibular third molar removal: a prospective split-mouth study, preliminary report. *Br Dent J.* 2012;213(12):597-601.
20. Sweet JB, Butler DP, Drager JL. Effects of lavage techniques with third molar surgery. *Oral Surg Oral Med Oral Pathol.* 1976;41(2):152-168.
21. Bonine FL. Effect of chlorhexidine rinse on the incidence of dry socket in impacted mandibular third molar extraction sites. *Oral Surg Oral Med Oral Pathol Oral Radiol Endod.* 1995;79(2):154-157; discussion 157-158.
22. Hall HD, Bildman BS, Hand CD. Prevention of dry socket with local application of tetracycline. *J Oral Surg.* 1971;29(1):35-37.
23. Sanchis JM, Saez U, Penarrocha M, Gay C. Tetracycline compound placement to prevent dry socket: a postoperative study of 200 impacted mandibular third molars. *J Oral Maxillofac Surg.* 2004;62(5):587-591.
24. Reekie D, Downes P, Devlin CV, Nixon GM, Devlin H. The prevention of 'dry socket' with topical metronidazole in general dental practice. *Br Dent J.* 2006;200(4):210-213; discussion 206; quiz 226.
25. Al-Saffar MT, Al-Sandook TA, Suleiman MS. Protective effect of topical ibuprofen against dry socket. *Al-Rafidain Dent J.* 2008;8(2): 136-143.
26. Syrjanen SM, Syrjanen KJ. A new combination of drugs intended to be used as a preventative measure for the postextraction complications. A preliminary report. *Int J Oral Surg.* 1981;10(1):17-22.
27. Poor MR, Hall JE, Poor AS. Reduction in the incidence of alveolar osteitis in patients treated with the SaliCept Patch, containing Acemannan Hydrogel. *J Oral Maxillofac Surg.* 2002;60(4):374-379; discussion 379.
28. Brekke JH, Olson RA, Scully JR, Osborn DB. Influence of poly lactic acid mesh on the incidence of localized osteitis. *Oral Surg Oral Med Oral Pathol.* 1983;56(3): 240-245.
29. Bloomer CR. Alveolar osteitis prevention by immediate placement of medicated packing. *Oral Surg Oral Med Oral Pathol Oral Radiol Endod.* 2000;90(3):282-284.
30. Suleiman AM. Influence of Surgical gauze on the incidence of dry socket after wisdom tooth extraction. *East Mediterr Health J.* 2006;12(3-4):440-445.
31. Schatz JP, Fiore-Donno G, Henning G. Fibrinolytic alveolitis and its prevention. *Int J Oral Maxillofac Surg.* 1987;16(2):175-183.
32. Pfizer, Inc. *Gelfoam* [product information]. Available at: http://www.pfizer.com/files/products/uspi_gelfoam_plus.pdf. Accessed March 18, 2015.
33. Johnson & Johnson. *Surgical* [product information]. Available at: <http://www.ethicon.com/healthcare-professionals/products/biosurgery/surgical-family-of-absorbable-hemostats/surgical-original-absorbable-hemostat#!overview>. Accessed March 18, 2015.
34. Unicare Biomedical, Inc. *BenaCel Dental Dressing* [product information]. Available at: <http://www.unicarebiomedical.com/dental-supplies/benacel.html>. Accessed March 18, 2015.
35. Swanson AE. A double-blind study on the effectiveness of tetracycline in reducing the incidence of fibrinolytic alveolitis. *J Oral Maxillofac Surg.* 1989;47(2):165-167.
36. Goldman DR, Kilgore DS, Panzer JD, Atkinson WH. Prevention of dry socket by local application of lincomycin in Gelfoam. *Oral Surg Oral Med Oral Pathol.* 1973; 35(4):472-474.
37. Fridrich KL, Olson RA. Alveolar osteitis following surgical removal of mandibular third molars. *Anesth Prog.* 1990;37(1):32-41.
38. Johnson WS, Blanton EE. An evaluation of 9-aminoacidine/Gelfoam to reduce dry socket formation. *Oral Surg Oral Med Oral Pathol.* 1988;66(2):167-170.
39. Huang WT, Lin MS, Yang S. Benacel for post-extraction wound healing, *Unicare Biomedical Internal Research Report*, May 9, 2011.
40. Nusair YM, Younis MH. Prevalence, clinical picture, and risk factors of dry socket in a Jordanian dental teaching center. *J Contemp Dent Pract.* 2007;8(3):53-63.

Manufacturers

Johnson & Johnson, Skillman, NJ
800.690.1826, www.jnj.com
Pfizer, Inc., New York, NY
800.879.3477, www.pfizer.com
Unicare Biomedical, Inc., Laguna Hills, CA
949.305.9600, www.unicarebiomedical.com